

# Sheep and Goat Neonate Necropsy Manual

## Introduction: Why would we want to do a neonatal necropsy?

- Performing a necropsy on a neonate is extremely important. Complete examination of the neonate will provide you with information that is essential to the farmer. Identification of any infectious diseases will allow the farmer to take action to prevent further spread of the disease and additional deaths of both neonates and adults. You may also identify causes of death related to management issues such as hypothermia, starvation, and parasitism. Identifying these issues can help the farmer do a better job with neonate care in the future.

## What you will need:

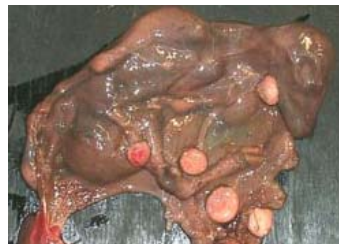- **Personal Protective Equipment (PPE):** It is crucial to wear PPE while performing the necropsy. This includes gloves, scrubs/coveralls, and in the case of an aborted fetus, goggles and a mask. Be sure to wash your hands very well afterwards, and dispose of the carcass appropriately
- **Tools:** You will need a necropsy knife, hoof trimmers for clipping bone, a pen, a beaker of water for floating lung tissue, proper disposal methods, containers for sample submission, and a camera for documenting lesions.

## THE NECROPSY

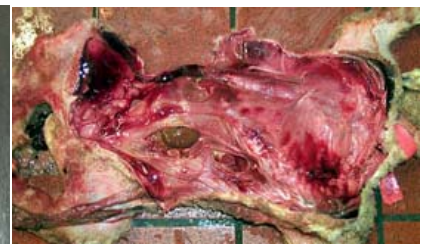### General assessment

- Check the lamb for ear tags, tattoos and/or painted numbers on the side of the lamb, making a note of any colors that you find.
- Observe the overall body condition of the lamb. It is helpful to hold the lamb up by the forelimbs and make note of the amount of abdominal distention. If it is convex, it probably means that the lamb ate before it died. If concave, it may mean that the lamb did not eat a meal.
- Weigh the lamb. If necessary, you can use a human scale or a hanging scale with a tared bucket.
- Determine the sex of lamb.
- Note the coloration of the lamb and if possible the breed.
- Determine if the lamb is fresh, autolyzed or mummified. An autolyzed lamb will have red, gelatinous fluid underneath the skin, whereas the mummified fetus will be dried and may not be full term.

Mummified fetuses are usually uniformly brown in color with sunken eye sockets, and their tissues are not useful for laboratory findings.

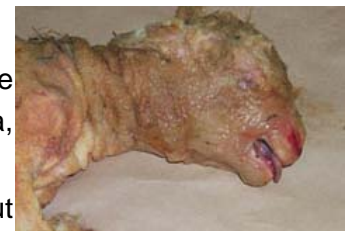

Mummy



Autolysis

- Lift the tail and look for meconium staining. This will appear as a brown/yellow stain around the perineum, underside of tail and/or legs. This indicates that the animal lived long enough to have its first bowel movement and also that it has a patent digestive tract. However, if the whole animal is stained yellow, this may mean that it was stressed and anoxic while in utero and passed its meconium before birth. This is easier to see on sheep wool than on kid hair.
- If there is a placenta attached, describe it. Is it thickened? Is it a complete placenta? If the fetus is mummified, check the cotyledons for necrotic foci and mineralization since these lesions suggest Toxoplasmosis. If the placenta covers the nose, the lamb was dead prior to birth or failure of the amnion to break caused suffocation.
- Check the umbilicus: Is it dipped with iodine? Has it been clipped? If so, it was not stillborn.
- Check the feet! Are they dirty? If not, this may mean that the animal did not live long enough to walk.
- Look for swelling of the extremities.
- Examine the head and tongue for swelling, which may indicate that the lamb was stuck with its head outside of the ewe's vulva, leading to restriction of venous return from the head.
- Examine the animal for any anatomic abnormalities including but not limited to: cleft palate, cyclopia, arthrogryposis, entropion, and umbilical hernias
- Check for dehydration in a fresh lamb.

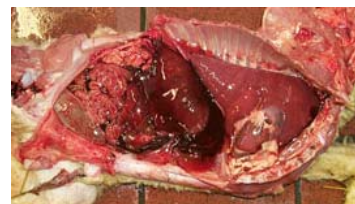

Dystocia

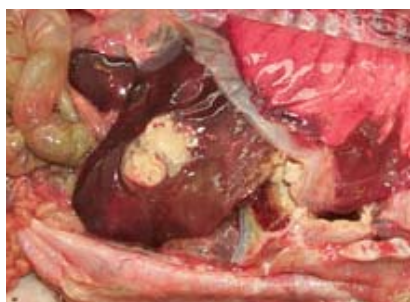### Beginning the Necropsy

- **Getting started**
  - o Place the lamb in left lateral recumbency with the limbs pointed toward you.
  - o Make your first cut as a stab incision into the right axilla. Place your knife into the stab incision, and using an upward and outward motion, extend the incision, taking care to keep the sharp edge of the knife on the underside of the skin. In this way, you will avoid dulling the knife by cutting the coarse wool. Undermine the musculature of the scapula to release the thoracic limb from the body wall and reflect it away from you.
  - o Next, repeat this process in the inguinal region. Extend this incision into the hip joint, releasing the musculature on the medial surface of the thigh and then cutting the ligament of the head of the femur. This will allow you to luxate the head of the femur and reflect the pelvic limb away from you.
  - o At this point, connect the two incisions so that you may reflect the skin of the body wall away from you. You may also want to reflect some of the skin on the ventral aspect of the lamb to expose more of the body cavity.
- **Entering the abdominal cavity**

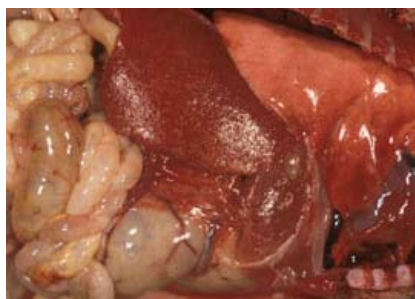- Carefully, cut into the abdominal cavity and reflect a flap of abdominal wall large enough to provide adequate visualization. Take care not to cut into any of the abdominal viscera.
- Look for free fluid or blood in the abdomen; hemorrhage possibly indicates liver capsule rupture (from dystocia or a crushing injury), among other causes.
- Assess all abdominal organs.



Liver Rupture



Fusobacterium Abscess



Listerial Hepatitis

- **Abomasum:** Make a cut into the abomasum to visualize the abomasal contents. Specifically look for the presence of milk.
  - **Liver:** Look for any lesions, abnormal coloration, rounded edges vs sharp edges, size etc. A large abscess may indicate a *Fusobacterium* infection from an umbilical infection. Septicemic lambs with *Listeria monocytogenes* may have multifocal necrosis of the liver, but may need to be diagnosed by histologic examination.
  - **Intestines:** Note the level of fullness of the intestines and the presence or absence of meconium. Run the length of the intestines and look for any areas of hemorrhage. Look for other abnormalities such as atresia or obstructions.
  - **Umbilical arteries:** Look for hemorrhage at the end of the arteries (on either side of the bladder), indicating that the lamb was alive when it separated from its placenta.
  - **Kidneys:** Examine the amount and color of perirenal (brown) fat; a normal neonate will have some perirenal fat, but a complete absence of fat is indicative of starvation as this fat is the last to be used. A stillborn will still have this fat. Observe the size and shape of the kidneys and note any lesions.
- Examine remaining abdominal structures, including the bladder and urinary tract, looking for any gross abnormalities.

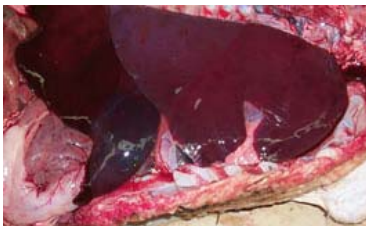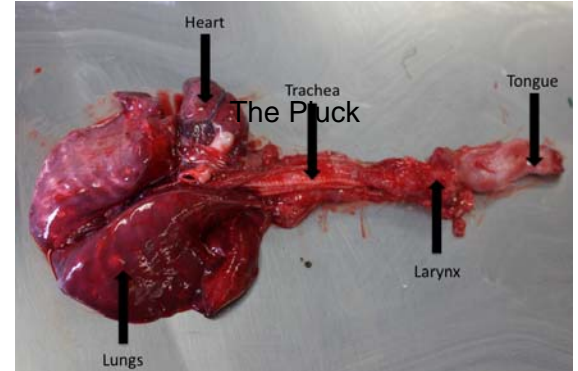
#### - Entering thoracic cavity

- Check the ribs for any fractures prior to cutting. An antemortem fracture will have some hemorrhage surrounding the break.
- Cut the diaphragm along the ribs. Then cut across the ribs through all of the costochondral junctions.
- Using a hoof clipper to cut the ribs dorsally or breaking with your hands, reflect the rib cage away from you.

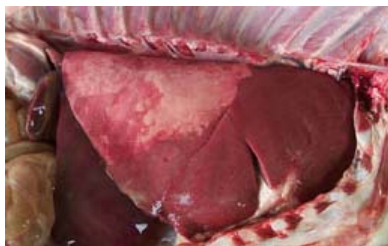
- Determine the amount of pericardial fat present. If there is none, starvation is a concern.
- Tent the pericardium and make a stab incision. Then, remove the pericardium from the heart.

- **Removing the pluck**

- The pluck consists of the tongue, larynx, trachea, esophagus, heart, and lungs. These organs should be removed as one complete unit.
- Before removing the pluck, incise the pericardial sac, looking for fluid or fibrin.
- Extend your original skin incision cranially, continuing through the mandibular symphysis.
- Start by lifting the tongue and releasing its attachments. Next, pull the tongue out through the cut previously made through the mandibular symphysis.
- Continue releasing the attachments of the larynx, cutting through the hyoid apparatus and releasing the esophagus and trachea which should still be attached to the tongue.
- Continue to cut any attachments while lifting up the pluck and pulling it out of the thorax.
- The final steps in removing the pluck involve severing the aorta near the heart, cutting the caudal vena cava and esophagus at the diaphragm, and releasing the attachment of the pericardial sac to the ventral thorax.



Stillbirth



*M. haemolytica*  
Cranioventral  
Bronchopneumonia

- **Examining the pluck**

- **Lungs**

- Examine the lungs for color, consistency, and lesions: healthy, oxygenated lungs are usually a pale pink color with a spongy consistency. Lungs that are diseased or those of a stillborn may be darker in color and have a firm feel.
- Specifically examine the lungs for the presence of atelectasis, pneumonia, consolidation, milk etc.
- *Mannheimia haemolytica* is a common

cause of cranioventral bronchopneumonia. The right cranial lobe is usually involved first. To diagnose pneumonia, the lungs can be almost any color, but they must be firm.

- A good test to see if the lungs were healthy or not is to cut off a piece and drop it into a container of water. Inflated lungs will float while lungs that are diseased or those that were never inflated will sink.
  - **Thyroid glands:** Identify the thyroid glands and unless very small, weigh the glands together.
  - **Trachea:** Cut along the length of the trachea examining for any obstructions, presence of milk, hemorrhages etc.
  - **Heart**
    - Examine the surface of the heart for any gross abnormalities. Then, cut into the four chambers of the heart and examine for any congenital abnormalities such as a ventricular septal defect or a patent foramen ovale, as well as for any other gross abnormalities.
- **Removing the head**
- Remove the head by using your blade to cut between the occipital bones of the skull and the atlas.
  - Remove the skin from the back of the head, holding onto one ear while removing the skin with the blade.
  - To open the skull, make two cuts with the hoof clippers, one on each side of the foramen magnum. Continue these cuts forward on each side, and join the cuts at the front of the calvarium.
  - Once you have made a big enough window by removing the calvarium, remove the brain carefully and using gravity to your advantage.
  - Examine the brain for abnormalities: Is there hydrocephalus, congestion, hemorrhage etc.
- **Final interpretation**
- Make your diagnosis as to the cause of death!