# Cornell Institute for Biology Teachers



Lab issue/rev. date: 9/30/98

**Title:** **The Tell-Tale Heart**

**Authors:** Mary Colvard, Cobleskill-Richmondville High School Cobleskill, New York
Dr. Marguerite Frongillo, Cornell University, Ithaca, New York

**Appropriate Level:** High School Biology: Regents, General, and Honors

**Abstract:** *The Tell Tale Heart* is an activity during which students familiarize themselves with the structure of the heart. They locate the atria, ventricles, and major blood vessels. Through "surgical" procedures, students perform coronary bypass surgery and correct patent ductus arteriosus. Human and dog hearts are compared in terms of common structure and defects.

**Special Notes:** *The Tell Tale Heart* requires a heart, dissecting equipment, and plastic straws.

**Time Required:** Approximately 60 minutes for the procedures.

**Living Environment:** **4-Content**:1-Living things: 1.2a-e; 5-Dynamic Equilibrium: 5.2a,h,j; 5.3a,b

# Additional Teacher Information

Have students work in surgical teams of two. Each group will need a fresh or preserved mammal heart. Sheep, beef, or deer hearts are all fine. Preserved hearts are easier to use because if students do not happen to complete the "surgery" during the first lab session, the heart can be packaged and saved until the students can return and complete the investigation.

## Materials:

- one pair of dissecting scissors
- one dissecting pan
- two probes
- masking or lab tape to label the straws
- one 16-cm section of narrow rubber tubing (Aquarium tubing will work, so would another straw if tubing is not available.)
- one pair of forceps
- one pair of latex or vinyl gloves/student
- 2 straws cut in half
- a "needle" and 12 inches of bright thread
- a reference chart of the heart (this could be a large poster which clearly illustrates the chambers and major vessels.)

The "needles" will be used when simulating the repair of an opening in the patent ductus. Size 4 fish hooks that have had the barb flattened and the point pinched off work well. If fishhooks are not easily available or fixable, Christmas ornament hangers can be used. They are not as sturdy and the "eye" which must be threaded is on the large side and should be crimped.

# Background Information for Teacher

## Patent Ductus Arteriosus in Dogs

The ductus arteriosus is a normal embryonic connection between the pulmonary artery and the aorta. It is located distal to the bracheocephalic artery that supplies the forelimbs, but proximal to the subclavian and other arteries supplying the rear of the body.

The most common congenital disorder of the heart occurs when the ductus fails to close. In dogs this is a polygenic inherited trait that occurs in certain breeds, and is four times more common in females than in males.

Patent ductus arteriosus serves to increase the pressure of blood in the pulmonary artery, leading to pulmonary edema. This adversely affects gas exchange in the lungs. Small breeds with PDA typically die within a year, while large breeds may live for several years with the condition. Even in large dogs, it is important to act early and surgically correct the condition before the left ventricle becomes enlarged in response to pumping more blood than normal. This enlargement causes permanent damage to lung vessels and leads to enlargement of the valve between the left atrium and ventricle, which in turn permits backwards currents of blood from the left ventricle into the left atrium, the enlargement of the left atrium, and ultimately left atrial fibrillation and death.

The younger the animal at the time of the operation, the better the reported success rate for surgical repair. PDA repair has been done successfully in puppies weighing only 0.5 kg, although such a small size makes the operation a challenge for the surgeon.

## Patent Ductus Arteriosus in Humans

In the human fetus, a pair of umbilical arteries provides blood flow to the placenta. These arise from the internal iliac arteries and enter the umbilical cord. Oxygen and nutrients are brought to the fetus via blood that is returned from the placenta in the umbilical vein. This vein delivers blood to the capillaries within the developing liver and to the inferior vena cava through the ductus venosus.

The circulatory development of the fetus reflects the fact that it must extract oxygen not from inspired air but across the placenta. Also, during embryonic and fetal life, its lungs are collapsed. The capillaries are compressed and little blood flows through the lungs.

The interatrial and interventricular septa of the heart develop early. However, the interatrial partition remains functionally incomplete until the time of birth. The interatrial opening is called the ***foramen ovale*** and has a flap that acts as a valve. Blood is permitted to flow freely from the right atrium to the left atrium. Any backflow will close the valve and isolate the two chambers. Blood enters the fetal heart at the right atrium and bypasses the pulmonary circuit. Another short cut exists between the pulmonary and aortic trunks. This connection is called the ***ductus arteriosis*** and consists of a short, muscular vessel.

During diastole blood enters the right atrium and flows into the right ventricle. But about 25% of it also passes into the left atrium via the foramen ovale bypassing the pulmonary circuit. Also, over 90% of the

blood leaving the right ventricle passes through the ductus arteriosis and enters the systemic circuit rather than going to the lungs.

At birth, when the infant takes its first breath, the lungs expand and so do the pulmonary vessels. Blood rushes into the expanded vessels and with a few seconds, increasing oxygen levels stimulate the constriction of the ductus arteriosis. This serves to isolate pulmonary and aortic trunks. Also, as pressure rises in the left atrium, the flap closes the foramen ovale. It is permanently sealed after 48 hours. If the sealing process does not occur, the foramen remains open or ***patent***. This causes circulation to the lungs to be reduced and blood oxygenation to be low. The newborn soon becomes starved for oxygen and cyanosis develops causing the infant to look blue. This is one factor that can produce a "blue baby."

In adults, the interarterial septum has a shallow depression at the site of the foramen ovale. This depression is called the fossa ovalis. A fibrous cord is all that remains of the ductus arteriosis. It is referred to as the ligamentum arteriosum.

If the ductus arteriosis is not stimulated to constrict completely, a large volume of blood will bypass the lungs. This is referred to as patent ductus arteriosis and also results in cyanosis. Ventricular septal defect, atrioventricular defect, transposition of the great vessels, and a complex group of heart and circulatory defects called *tetralogy of Fallot* are all congenital circulatory problems that can produce a "blue baby." This lab is primarily addressing patent ductus arteriosis since it involves students locating pulmonary vessels and the aorta.

## Answers to Questions

2. Why is patent ductus a dangerous condition? Use your illustration to assist you when writing your explanation.

   *It is a congenital disorder of the heart that occurs when the ductus fails to close. Thus it reduces the oxygen available to cells.*

3. Which side of the heart should be called the "low $O_2$" side? Why?

   *The right side of the heart is the "low $O_2$" side. This is because the blood has just returned from the body where $O_2$ and $CO_2$ exchange has occurred.*

4. Where does the blood in the pulmonary vein come from?

   *The blood comes from the lungs.*

5. Name and describe three circulatory disorders not mentioned in this lab.

   *There are a large number of circulatory disorders students could research. Some might be: sickle cell anemia, hypertension, stroke, varicose veins, atherosclerosis, coronary thrombosis, heart murmur, etc.*

## References

Bowman, DD, 1995. *Georgis' Parasitology for Veterinarians*. 6th ed. Saunders, Phila.

Jackson, RF, 1987. *Microfilaricides*. Sem Vet Med and Surg, Sm Anim. 1987:44-47.

Orihel, TC, 1961. *Morphology of the Larval Stages of Dirofilaria immitis in the Dog*. J Parasit. 47:251-262.

Rawlings, CA, 1986. *Heartworm Disease in Dogs and Cats*. Saunders, Phila.

Todaro, WS, Morris, CD, and Heacock, NA, 1977. *Dirofilaria immitis and its Potential Mosquito Vectors in Central New York State*. Am J Vet Res. 38:1197-1200.

## The Tell-Tale Heart

New York State Learning Standards

**Standard 4: Content**

Key Idea 1: Living things are both similar and to and different from each other and from nonliving things.

1.2- Describe and explain the structures and functions of the human body at different organizational levels.

Key Idea 5: Organisms maintain a dynamic equilibrium that sustains life.

5.2- Explain disease as a failure of homeostasis

5.3- Relate processes at the system level to the cellular level in order to explain dynamic equilibrium in multicelled organisms.

# The Tell-Tale Heart

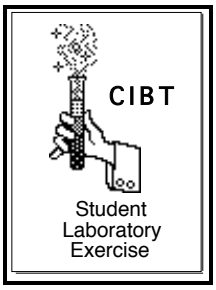


**Name** _____

## Introduction to the Heart

The main function of the heart is to keep blood constantly moving throughout the body. In mammals the heart is a large organ composed of cardiac muscle cells rich in mitochondria. Mammal hearts have four chambers. The two upper chambers, known as atria or auricles, are thin-walled and designed to receive blood. The two lower chambers, known as ventricles, have much thicker walls and perform more work than the atria. Additionally, since the left ventricle must do even more work than the right, the mammal heart seems somewhat lopsided. It is critical that the heart remains healthy and undamaged.

There are constant assaults on the vigor and efficiency of the heart. For centuries scientists have been working on finding the causes of (and solutions to) many cardiovascular problems in humans and other mammals. As early as the 1600's, heart movement and blood circulation was studied in dogs. In 1665 the first transfusion was done using quills and silver tubes to transfer the blood from one dog to another. Since its cardiovascular and respiratory system closely resembles that of a small human, the dog has served as a model in the development of treatments that have successfully saved the lives of many dogs and humans. Surgical procedures have been developed to open narrowed arteries in the neck or leg, and diseased and damaged arteries in the heart can be surgically by-passed. Many congenital defects (those one is born with) can be repaired.

Parasitic worms may reduce heart function in dogs and may even result in death. Mosquitoes are known vectors of this nasty, life-threatening parasite, commonly called the dog heartworm. Heart anatomy will be examined as it relates to heartworm infection and also to a common congenital defect found in humans, dogs, and cats known as patent ductus arteriosis (PDA). Symptoms and methods of treatment are similar in all three species. In humans this condition is commonly referred to as "blue baby". You will become familiar with the basic structure of the heart and the repair of both patent ductus arteriosis and an acquired defect that requires bypass surgery. You will examine the structure of the mammalian heart to learn how the heart functions and perform surgery to "repair" damaged parts.

In a normal fetus, the ductus arteriosus diverts blood from the pulmonary artery around the undeveloped lungs to the aorta. This is because the fetus does not get oxygen from the air but across the placenta from the mother's blood. The lungs do not expand until the baby is born and takes its first breath. The increase in oxygen in the blood causes the ductus to constrict and shut down. In dogs and cats, the ductus arteriosis is short. It is usually only about one centimeter long and one centimeter wide. In the human, it is much larger. The congenital defect, PDA, results when the connection between the aorta and the pulmonary artery fails to close after birth and blood does not follow the pathway it should in the normal adult organism. The word "patent" means open. Thus the term "patent ductus arteriosis" means that the connection, the ductus arteriosis, remains open when it should be closed off.

PDA occurs in about 1:750 live births in dogs. It is much less common in cats. The disorder is hereditary and more common in poodles, German shepherds, Shetland sheep dogs, collies, Pomeranians, and spaniels. The problem is often detected when the dog or cat is brought to the veterinarians for vaccinations. When using a stethoscope during a routine check of the heart, a murmur can be heard. When coupled with other symptoms, the veterinarian can make a diagnosis of ductus arteriosus. The murmur results from damage done to a heart valve when the ductus arteriosis does not close. (Humans have heart murmurs, too. These are often due to the backflow of blood as the result of a faulty heart valve. It is often not related to this problem.) If the disease is untreated, the left side of the animal's heart will enlarge and eventually fail to function. There will be gradual and increased damage to the pulmonary vessels, followed by valve failure and ultimately death. A pet owner should watch for symptoms such as a lack of energy, irregular or rapid breathing, coughing, fainting, and poor growth. Afflicted animals often have weak rear legs due to the way the blood flow is incorrectly directed. This is because the blood supply to the abdomen and rear legs is incompletely oxygenated, while the upper part of the body is normal.

In a human baby, the heart sounds would also be abnormal. There could be a heart murmur just as with a puppy or kitten. Cyanosis (a color change) also results. In dogs the lack of a healthy pink flesh tone can be detected by examining the gums. In humans, the baby takes on a bluish color due to a lack of oxygen. This is why the disease is sometimes called "blue baby."

Another heart problem you will repair is acquired. Coronary circulation is important in maintaining the health of the heart muscle itself. Sometimes arteries feeding blood to the heart narrow and become blocked with plaque (cholesterol). One way of combating this problem is through coronary bypass surgery. A vein removed from the patient's leg is typically used as the bypass vessel. It diverts some of the blood leaving the left side of the heart to a coronary artery, bypassing the blocked section.

## Materials

- mammal heart (pig or sheep), preserved or fresh
- 2 drinking straws cut in half at the middle
- dissecting equipment (pan, scissors, scalpel, forceps, probe)
- 16 cm section of plastic tubing
- disposable latex gloves
- masking or lab tape
- bright thread
- "needle"

## Procedure

***Which way is up?***

To perform heart surgery, you want the patient on his or her back. The ventral surface of the heart should be facing you. The difference during this operation is that the patient is not with you! You are working only on the heart.

NOTE: Always wear protective gloves when handling animal tissue.

1. To decide which way the heart should be positioned on your dissecting pan, first find the two small, pale, floppy ear-like structures at the top of the heart. These are the atria or auricles. The term auricle is just another way of saying "little ears."

2. Examine Figure 1. Feel the heart at points A and B. One side should feel much tougher or harder than the other. The tougher/harder side is made of a thicker wall of muscle. It is the left ventricle. The other side is thinner and does not feel as hard.

3. Position the heart so that the left ventricle is on your right and the atria are away from you. Look for a large, distinct coronary artery. It seems to separate the heart into two sections. Use the following illustration to guide you in positioning your specimen on the dissecting pan.

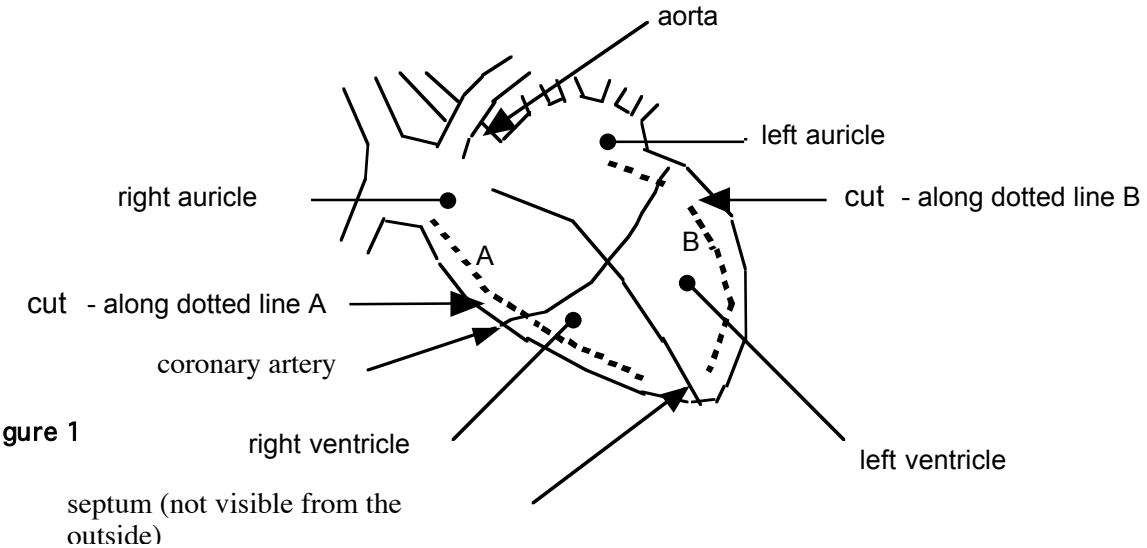


Figure 1

***Getting Acquainted***

4. With the scalpel, cut the heart approximately along line A and then along line B. Cut deep enough to pass all the way through the muscle. *Do not join the cut you make at A with B*. Keep the two incisions as separate openings into the heart chambers. You should be able to see that one wall is much thicker than the other wall.

5. Look inside the right and left ventricles. Notice the cords stretching from the floor of each ventricle to the atrium above it. These cords are associated with the valves. Also notice the solid wall that separates the right and left sides of the heart.

6. Push your index finger through the cut you made in the right ventricle. Move your finger around until you can feel it enter and then see it move around in the right atrium.

7. Move your finger in the right atrium until you see it going into a large blood vessel. This vessel is the vena cava.

8. Remove your finger and cut away some of the fat and connective tissue surrounding the vena cava; it will make it easier to see the vessel. Put a straw in the vena cava. Work it back through the right auricle and into the right ventricle. With a piece of tape, label the straw—*vena cava/right side*.

9. Again put your finger into the right ventricle and push your finger out of a large blood vessel (do not go back into the right atrium). This new vessel should be the pulmonary artery. Push a straw through the ventricle into the pulmonary artery and label it—*pulmonary artery/right*.

10. Next put your finger into the left ventricle. Move your finger up but do not go into the left atrium. Find the blood vessel that leads out of the left ventricle. This is the aorta. Put a straw into the aorta and down into the left ventricle. With a piece of tape, label the straw—*aorta/left side*.

11. Clean away fat and connective tissue at the base of the aorta.

## *Correcting patent ductus arteriosus*

12. Now that you have identified the aorta and the pulmonary artery, you are ready to correct patent ductus arteriosus in a puppy or "blue baby" syndrome in a human. Locate the thin bridge of ligament between the pulmonary artery and the aorta. In an individual with patent ductus arteriosus, this ligament would be an open vessel carrying blood still loaded with $CO_2$ into the aorta and then through the body, bypassing the lungs.

13. A surgeon would now stitch the opening in the ligament between the vessels closed. To simulate this, thread the needle provided and make two or three looped "stitches" in the ligament separating the pulmonary artery and the aorta. When done, cut the "needle" from the tread, leaving the stitches in place. The flow of blood, once the opening is sealed, will follow the correct path. An adequate supply of oxygenated blood will travel to all parts of the body.

    Follow the pathway of blood from the vena cava where it enters the heart, to the aorta where it finally leaves the heart to circulate through the rest of the body. Fill in the spaces with the names of the structures through which the blood must pass.

    The vena cava brings blood loaded with $CO_2$ to the (a)_____, which delivers the blood to the (b)_____. This chamber pumps the $CO_2$ loaded blood through the (c)_____ to the (d)_____ where the blood gives up its $CO_2$ and takes in (e)_____. The blood then returns to the heart through the (f)_____ and enters the (g)_____. This chamber delivers blood into the (h)_____ which pumps it through the (i)_____ to all parts of the body.

*Coronary Bypass Surgery*

Bypass surgery is used to bring a good supply of blood around a blockage to a damaged area of the heart.

14. Locate the straw labeled *aorta/left side*. Make a small hole in the base of the aorta and force one end of the "bypass" vessel (rubber tubing) into the opening.

15. Locate a coronary artery on the surface of the left ventricle. Make a hole in the artery (do not cut all the way through). Force the free end of the bypass vessel into this opening. Refer to Figure 2. In reality, the surgeon would have located the region of the heart receiving an inadequate supply of blood. The bypass vessel would then direct blood to that area.

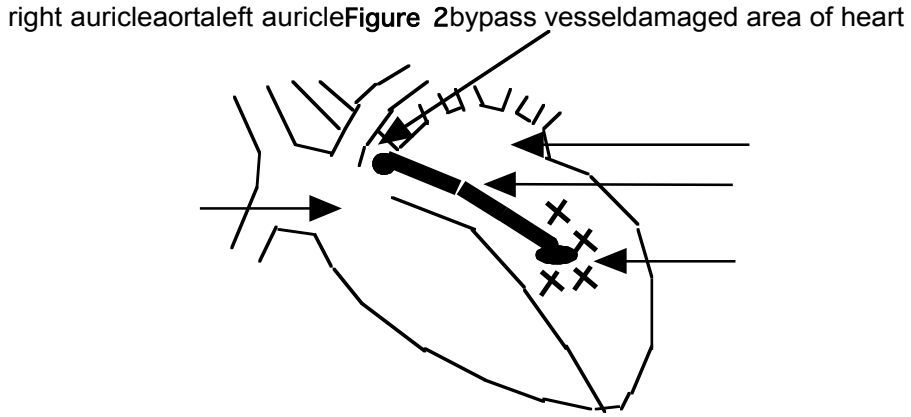

**Figure 2**

## Analysis

***Answer the following questions on your own paper, using complete sentences.***

1. Make a diagram illustrating the flow of blood in a puppy with congenital patent ductus arteriosus.

2. Why is patent ductus a dangerous condition? Use your illustration to assist you when writing your explanation.

3. Which side of the heart should be called the "low $O_2$" side? Why?

4. Where does the blood in the pulmonary vein come from?

5. Name and describe three circulatory disorders not mentioned in this lab.